

ORIGINAL ARTICLE

Open Access



# A population-based study of the clinical utility of $^{18}\text{F}$ -choline PET/CT for primary metastasis staging of high-risk prostate cancer

Henrik Kjölhede<sup>1,2\*</sup> , Helen Almquist<sup>3</sup>, Kerstin Lyttkens<sup>3</sup> and Ola Bratt<sup>1,4</sup>

\* Correspondence:

henrik.kjolhede@med.lu.se

<sup>1</sup>Department of Translational Medicine, Division of Urological Cancer, Lund University, Malmö, Sweden

<sup>2</sup>Department of Research and Development, Region Kronoberg, Växjö, Sweden

Full list of author information is available at the end of the article

## Abstract

**Background:** The clinical utility of  $^{18}\text{F}$ -choline positron emission tomography fused with computed tomography (PET/CT) in all men with high-risk prostate cancer is still uncertain, because of selection of patients in previous studies. Prohibitive costs are one reason for PET/CT not being recommended for primary metastasis staging in European or American guidelines. The purpose of this retrospective study was to assess the clinical utility of in for primary metastasis staging in as complete a population as possible of men with high-risk prostate cancer. A secondary purpose was to evaluate whether a subgroup of these men could omit metastasis staging.

**Results:** In total 410 men were identified with high-risk prostate cancer. After exclusions, 317 men were initially considered for curative treatment; 213 (67%) had a choline PET/CT, with 43 men (20%) having positive findings. The risk of lymph node metastasis according to the Briganti nomogram showed a good discrimination between men with low and high risk of positive scans. Among the 35% of men with <20% risk according to the nomogram, only 1% had a positive scan, compared to 30% positive scans among the men who had higher risk.

**Conclusion:**  $^{18}\text{F}$ -choline PET/CT detects suspected metastases in one fifth of men with high-risk prostate cancer and should be considered for routine use. For men with <20% risk of metastasis according to the Briganti nomogram, imaging for metastasis staging might be omitted.

**Keywords:** Prostate cancer, Pet/ct, Bone scintigraphy, Primary metastasis staging

## Background

The European Association of Urology (EAU) guidelines recommend conventional imaging with computed tomography (CT) or magnetic resonance imaging (MRI) together with  $^{99\text{m}}\text{Tc}$  bone scintigraphy (BS) – either as planar BS or single-photon emission computed tomography (SPECT) – as the current standard primary imaging for metastasis for men with high-risk prostate cancer (Mottet et al., 2017). For men with convincing findings of distant metastasis on imaging, curative treatment is usually considered inappropriate. Positron emission tomography fused with computed tomography (PET/CT) with  $^{11}\text{C}$ - or  $^{18}\text{F}$ -marked choline as tracer has for more than a decade been evaluated for

detecting bone and lymph node metastases in men with prostate cancer in a variety of settings (Wondergem et al., 2013; Ceci et al., 2015; Eyben & Kairemo, 2014; Mapelli & Picchio, 2015; Langsteger et al., 2011; Evangelista et al., 2016). The specificity of  $^{11}\text{C}$ - and  $^{18}\text{F}$ -choline PET/CT has generally been reported as high, around 90–95%, in primary lymph node staging (Evangelista et al., 2013). The sensitivity is lower, around 50%, but this is still higher than for CT, MRI and BS (Evangelista et al., 2016; Even-Sapir et al., 2006; Pinaquy et al., 2015; Evangelista et al., 2015; Heck et al., 2014).

We previously reported on the performance of  $^{18}\text{F}$ -choline PET/CT in 90 men with high-risk prostate cancer, defined as prostate specific antigen (PSA)  $\geq 20$  ng/mL and/or Gleason score (GS) 8–10, and a normal or inconclusive planar BS (Kjölhede et al., 2012). PET/CT detected widespread metastasis in 20%, which led to a change from curative to non-curative treatment, and less widespread metastasis in a further 19% of the men. However, the studied men were probably a selected group with more adverse prognostic factors and a higher than average risk of metastases, so the clinical value of choline PET/CT for the entire group of men with high-risk prostate cancer might have been overestimated.

Moreover, PET/CT is an expensive imaging modality and access to the machines is limited, so using it for all patients with high-risk prostate cancer would be costly and may put a difficult pressure on PET/CT resources. Known independent risk factors predicting metastatic disease are e.g. high PSA levels, high GS, locally advanced disease and proportion of positive biopsy cores (Risko et al., 2014; Porcaro et al., 2017). The Briganti nomogram weighs these factors for a score predicting the probability of finding lymph node metastasis with an extended pelvic lymph node dissection, and this nomogram has also been externally validated (Briganti et al., 2012; Hansen et al., 2013). These risk factors, or the Briganti nomogram, could possibly be used to define a subgroup of men where choline PET/CT has the greatest clinical utility and cost-effectiveness.

The aim of this study was to assess the overall clinical utility of  $^{18}\text{F}$ -choline PET/CT for primary metastasis staging of high-risk prostate cancer, in terms of detection rate of suspected metastasis. We also aimed at, if possible, identifying a subgroup of men with a low likelihood of positive scans, for which metastasis staging might be omitted.

## **Materials and methods**

### **Patients and ethics**

Through the Swedish National Prostate Cancer Registry (NPCR), we identified all men who were diagnosed histologically with high-risk prostate cancer from 1 May 2013 (the first date from which choline PET/CT was recommended in the clinical guidelines) to 31 Dec 2014 (the last date for which full and validated registry data was available at the time of data collection) in the counties Skåne and Kronoberg, both of which are part of the Southern Healthcare Region in Sweden. The NPCR has a validated coverage of >98% (Tomic et al., 2015). High-risk prostate cancer was defined as clinical tumor stage T3 and/or PSA > 20 ng/mL and/or GS 8–10 (Heidenreich et al., 2014). All still living patients gave written informed consent, while consent was assumed for deceased patients, according to Swedish law. The study protocol was approved by the Regional Ethics Committee in Lund (Dnr 2016/61).

### Data acquisition

PSA levels at diagnosis, GS at diagnosis, and clinical tumor stages were acquired from the NPCR. All other data was acquired retrospectively from medical records. The PSA levels at diagnosis and Gleason grades registered in the NPCR were validated in the medical records. The number of biopsy cores (both positive and total), treatment intent (curative or non-curative), results of imaging for metastasis staging, and final treatment were recorded. The proportion of positive biopsy cores was calculated as a percentage, from 6% (1 of 16 cores) to 100%, except for three men who were diagnosed on trans-urethral resection of the prostate (TUR-P). The risk of lymph node metastasis for each individual man was calculated with the Briganti nomogram using the PSA levels, primary and secondary Gleason grades, clinical tumor stages and the proportion of positive biopsy scores. Men who were not considered for curative treatment before any further evaluations had been done were excluded from any further analyses.

### Imaging

$^{18}\text{F}$ -choline PET/CT scans were performed as previously described (Kjölhede et al., 2012). In short, the scans were acquired with an integrated PET/CT system (Philips Gemini TF, Philips Medical Systems, Cleveland, OH, USA) at the Centre for Medical Imaging and Physiology, Skåne University Hospital in either Lund or Malmö. Whole-body PET was acquired 1–1.5 h after i.v. injection of 4 MBq/kg of  $^{18}\text{F}$ -fluorocholine with 2 min per bed position. A diagnostic quality CT scan was acquired immediately before the PET scan with oral and i.v. contrast given, with scans without i.v. contrast, in arterial phase, and in the portal phase. All PET/CT scans were jointly interpreted by a nuclear medicine physician and a radiologist, who both had access to any prior imaging performed. BS with  $^{99\text{m}}\text{Tc}$ -MDP were performed as planar BS, in some cases with an additional SPECT and low-dose computed tomography (SPECT/CT) acquisition at the discretion of the nuclear medicine physician responsible for interpreting the images. The PET/CT scans were each categorized as “positive”, “inconclusive”, or “negative”. Positive scans were defined as having lymph nodes in the pelvis (Cloquet’s node excluded) or retroperitoneally along the aorta or vena cava, that were either enlarged ( $\geq 1$  cm short-axis) on CT images or had a distinct choline uptake by visual estimation, or having skeletal sites with distinct choline uptake without evidence of other pathology on CT images. Negative scans were defined as having no enlarged lymph nodes and no increased choline uptake in those defined locales. Inconclusive scans were those with suspect findings that did not qualify as “positive”.

### Statistics

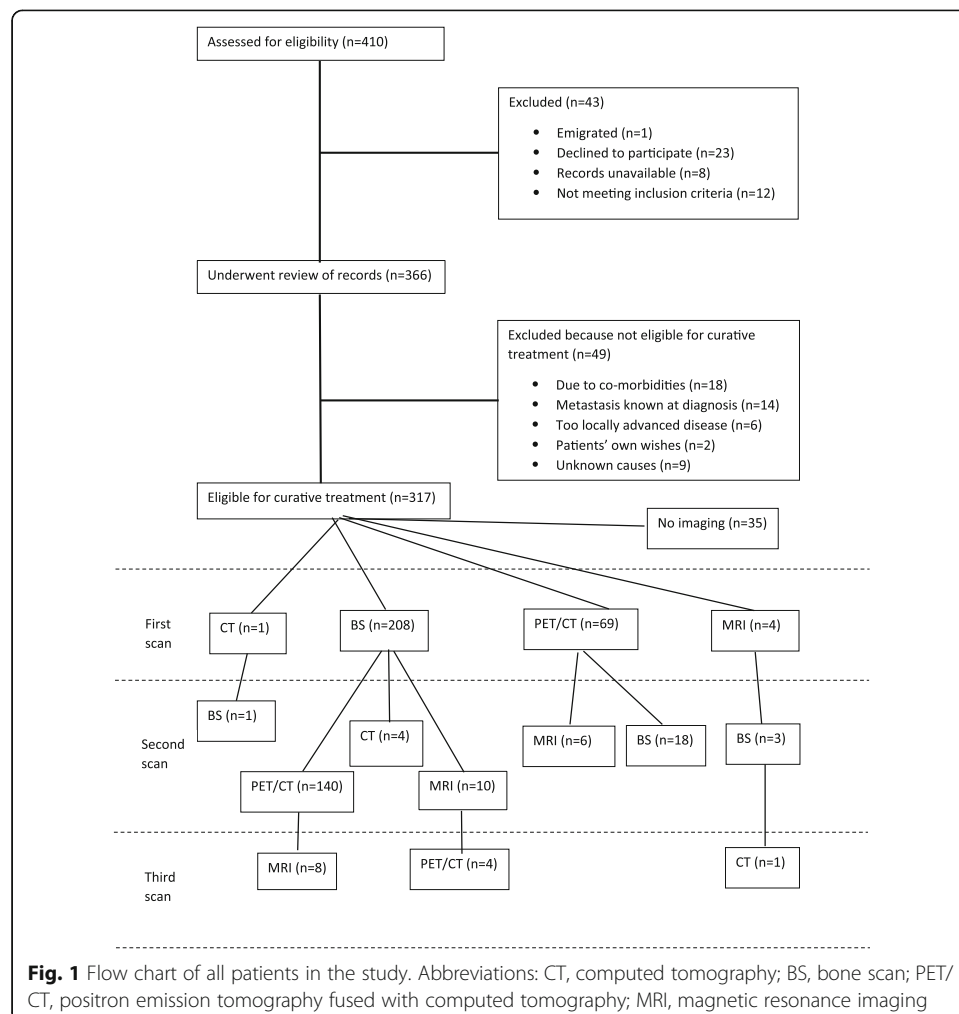
Mann-Whitney’s U test was used for continuous and Pearson’s  $\chi^2$  test for categorical variables to compare the groups who did or did not perform a choline PET/CT. Multiple logistic regression was used to calculate odds ratios (OR) with 95% confidence intervals (CI) for factors predicting positive choline PET/CT findings. For this purpose, clinical T stage before screening procedures was categorized as  $<$  or  $\geq$  T3, GS as  $<$  or  $\geq$  8, and PSA as  $<$  or  $\geq$  20 ng/ml, while the proportion of positive biopsy cores and the probability of lymph node metastasis according to the Briganti nomogram (Briganti et al., 2012) were analyzed as continuous variables. The three patients who were

diagnosed on TUR-P were excluded from the logistic regression, since the proportion of positive biopsy cores and Briganti score could not be calculated. IBM SPSS Statistics 23 (IBM Corp., NY, USA) was used for statistical analysis. A Briganti score cut-off was chosen to allow for a substantial reduction of the number scans performed, without missing more than a few positive scans.

## Results

A total of 410 men were registered in the NPCR as diagnosed with high-risk prostate cancer in the two counties from 1 May 2013 to 31 Dec 2014. Exclusions and all imaging performed are detailed in Fig. 1.

Of the 317 men who were planned for curative treatment and remained in the study after exclusions, a total of 213 (67%) had a choline PET/CT. A further six men had planned PET/CT scans cancelled because of unequivocal findings of metastasis on BS. The clinical characteristics of these 317 men are shown in Table 1. Men who had a PET/CT scan had significantly higher PSA values, a greater proportion of positive biopsies, more high-risk criteria (T3–4, GS 8–10 or PSA  $\geq$  20 ng/ml), and a higher probability of lymph node metastasis according to the Briganti nomogram (all  $p \leq 0.01$ ). There were no significant differences in age at diagnosis, in clinical local tumor stage, or in GS.



**Table 1** The clinical characteristics of the men included in the study who were initially considered for curative treatment, categorized by whether choline PET/CT was performed or not

	No PET/CT <i>n</i> = 104	PET/CT <i>n</i> = 213
Age, yrs		
Mean (SD)	67.6 (4.9)	68.3 (5.5)
PSA, ng/ml		
Median (IQR)	9.3 (6.1–22)	20 (8.6–37)
Gleason Score, <i>n</i> (%)		
3 + 3	2 (2)	8 (4)
3 + 4	14 (14)	29 (14)
4 + 3	7 (7)	29 (14)
4 + 4/3 + 5/5 + 3	43 (41)	49 (23)
4 + 5/5 + 4/5 + 5	38 (37)	98 (46)
Clinical tumor stage, <i>n</i> (%)		
TX	1 (1)	
T1	39 (38)	60 (28)
T2	37 (36)	79 (37)
T3	25 (24)	72 (34)
T4	2 (2)	2 (1)
Proportion of positive biopsy cores, %		
Median (IQR)	50 (20–67)	64 (40–92)
No. high-risk criteria, <i>n</i> (%)		
1	80 (77)	119 (56)
2	15 (14)	69 (32)
3	9 (9)	25 (12)
Probability of N1 <sup>a</sup> , %		
Median (IQR)	5 (5–35)	35 (15–65)
Primary treatment given after all evaluations, <i>n</i> (%)		
None	3 (3)	1 (1)
ADT	18 (17)	40 (19)
RP	66 (64)	67 (32)
RT	17 (16)	105 (49)

PET/CT positron-emission tomography fused with computed tomography, PSA prostate specific antigen, IQR inter-quartile range, ADT androgen deprivation therapy, RP radical prostatectomy, RT radiation therapy

<sup>a</sup>Risk of lymph node metastases according to the Briganti nomogram (Briganti et al., 2012)

Of the 213 men who had a choline PET/CT, 43 (20%) had positive findings, 51 (24%) had an inconclusive scan, and 119 (56%) had no abnormal findings. Of the 43 men with positive findings, 12 (28%) had positive skeletal sites (stage cM1b/c), 14 (33%) had positive retroperitoneal lymph nodes above the aortic bifurcation (stage cM1a), while 17 (40%) had positive pelvic lymph nodes only (stage cN1), with either pathologically enlarged or distinct choline uptake (or both). All lymph nodes that were pathologically enlarged lymph nodes also had distinct choline uptake. Two of the men with positive skeletal sites had no positive lymph nodes. Of the 162 men who performed both a PET/CT and a BS, seven had positive skeletal findings on the BS which were all detected by choline PET/CT. Of the 144 men who performed a BS before the PET/CT, 139 had normal or inconclusive findings on BS. Of these, 31 men (22%) had positive

PET/CT findings. The management was changed from curative to non-curative for 40 of the 213 men (19%) due to the PET/CT findings. All 40 men who received non-curative treatment had hormonal therapy. Two of them also had docetaxel and eight received palliative prostate radiation therapy.

Logistic regression analysis of possible predictive factors of positive findings on choline PET/CT are shown in Table 2, with the Briganti nomogram showing best discrimination with an AUC of 0.82 (Fig. 2). Figure 3 shows the results of the PET/CT scans grouped by their risk of metastasis. The ratio of inconclusive to negative scans was not significantly different between the risk groups ( $p = 0.87$ ).

Almost all men with positive choline PET/CT findings (98%) had  $\geq 20\%$  risk of lymph node metastasis according to the Briganti nomogram. In this  $\geq 20\%$  risk group, which constituted 65% of the 213 men who performed a PET/CT scan, 30% had positive PET/CT findings. Among the remaining 35% of the men, with  $< 20\%$  risk of lymph node metastasis, only 1% had positive PET/CT findings. In the whole group of 317 men planned for curative treatment (except for the three diagnosed with TUR-P), 45% had  $< 20\%$  risk of lymph node metastasis. The number of high-risk criteria did not discriminate between men with positive versus negative PET/CT scans as accurately as the Briganti nomogram; as many as 12% of the 119 men with only one high-risk criterion had positive scans.

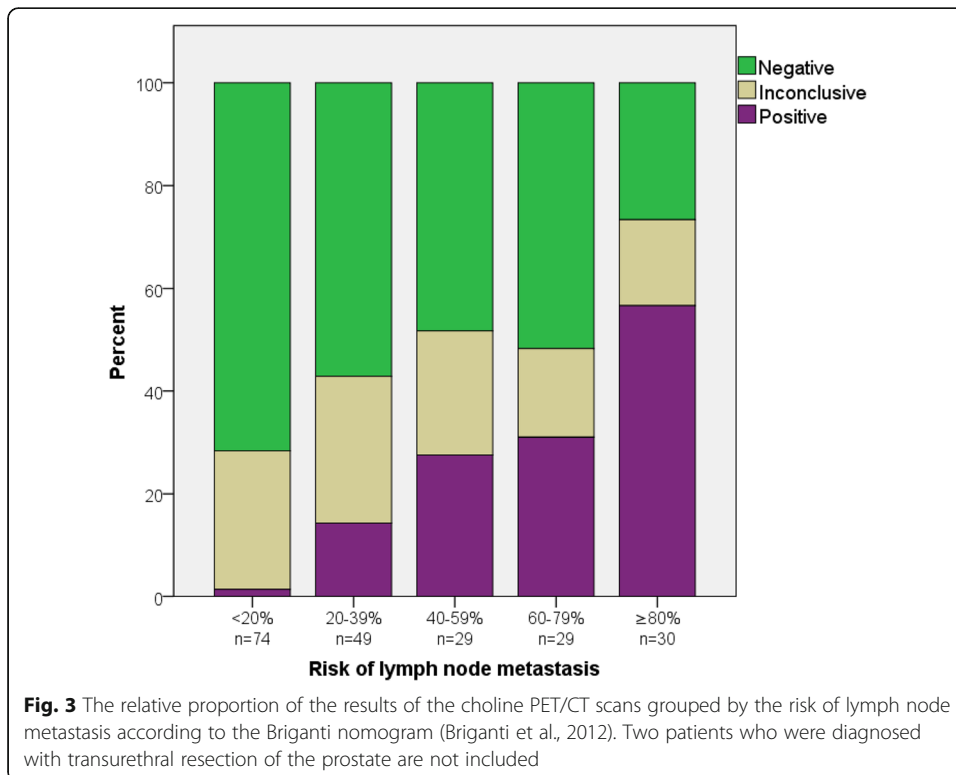
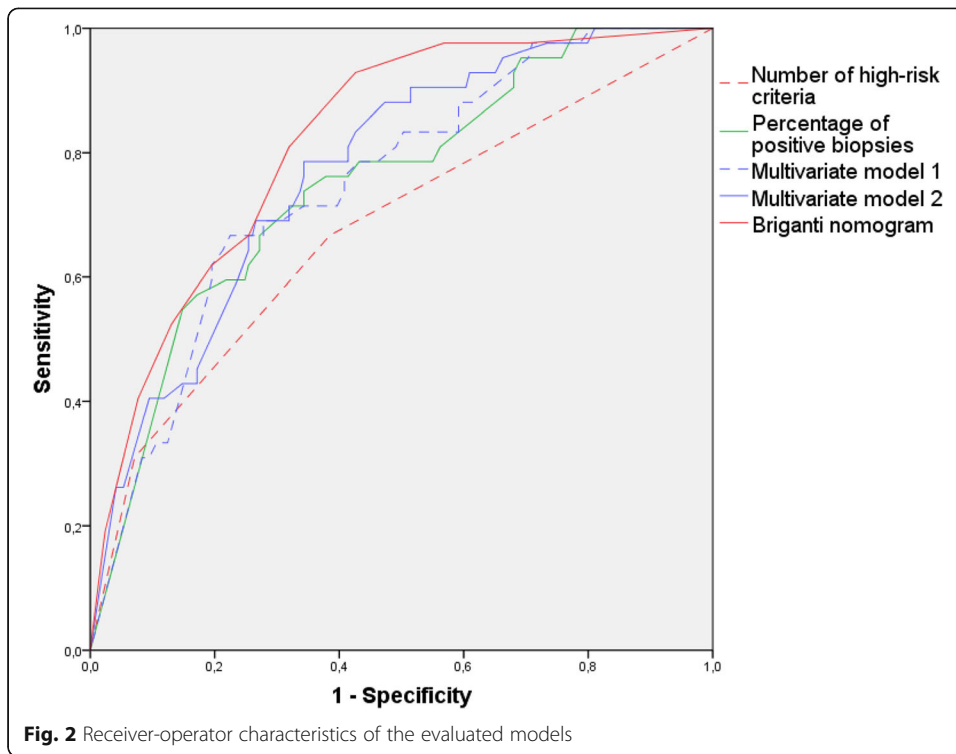
**Discussion**

In this population-based study of men with high-risk prostate cancer initially considered for curative treatment, 20% had positive  $^{18}\text{F}$ -choline PET/CT findings, which could potentially change their clinical management. The probability of lymph node metastasis according to

**Table 2** Logistic regression analysis of factors predictive of positive findings on  $^{18}\text{F}$ -choline PET/CT. PSA, Gleason score and clinical local tumor stage were each analyzed as dichotomized variables, as a high-risk criterion or not. The percentage positive biopsy cores and the probability of lymph node metastasis according to the Briganti nomogram were analyzed as continuous variables with an odds ratio calculated for 10% increments. The area-under-the-curve for each univariate and multivariate model is shown to compare the models. For the multivariate models, the independent variables that were significant on univariate analyses were included. In model 1, the individual high-risk criteria were used, while in model 2 the sum of high-risk criteria were used. The risk of lymph node metastasis according to the Briganti nomogram was only analysed univariately, since it incorporates all the other variables

	Univariate			Multivariate model 1		Multivariate model 2	
	OR (95% CI)	p	AUC	OR (95% CI)	p	OR (95% CI)	p
PSA < vs $\geq 20$ ng/ml	2.0 (1.0–4.0)	.05	.59 (.50–.69)	1.6 (0.8–3.5)	.198		
GS < vs $\geq 8$	1.9 (0.8–4.1)	.13					
T < vs $\geq 3$	2.7 (1.4–5.3)	.005	.61 (.51–.71)	1.8 (0.8–3.7)	.141		
Proportion positive biopsy cores	1.4 (1.2–1.7)	<.001	.75 (.67–.83)	1.4 (1.2–1.6)	<.001	1.4 (1.1–1.6)	<.001
No. high-risk criteria			.68 (.58–.77)				
1 (ref)	1					1	
2	2.3 (1.0–5.0)	.043				1.7 (0.8–4.0)	.199
3	8.1 (3.1–21)	<.001				3.9 (1.4–11)	.010
Probability of N1 <sup>a</sup>	1.5 (1.3–1.8)	<.001	.82 (.75–.88)				

OR odds ratio, CI confidence interval, PSA prostate specific antigen, T clinical local tumor stage, AUC area-under-the-curve  
<sup>a</sup>Probability of lymph node metastases according to the Briganti nomogram (Briganti et al., 2012)



the Briganti nomogram with a cut-off of 20% discriminated between men with a high (30%) and men with a low (1%) chance of a positive PET/CT scan.

Previous studies on primary prostate cancer staging with choline PET/CT have reported quite variable detection rates for lymph node metastases on choline PET/CT, likely because of differences in prognostic factors among included patients. A systematic review and meta-analysis showed an overall rate of positive choline PET/CT findings of 16% in a total of 661 men, which is well in accordance with the present results (Eyben & Kairemo, 2014). Evangelista and co-workers in a recent review found detection rates of lymph node metastases varying between 11 and 93% (Evangelista et al., 2016). These results underscore the need for selecting the right patients for PET/CT scans.

Like in the present study, Schiavina et al. also evaluated, amongst others, the Briganti nomogram in relation to  $^{11}\text{C}$ -choline PET/CT for predicting lymph node metastasis in 57 men and found no statistically significant differences in the AUC between choline PET/CT and the Briganti nomogram (Schiavina et al., 2008), but they made no attempt to define which patients most or least benefited from the scans. Briganti and co-workers investigated the clinical utility of BS in a large cohort of men with newly diagnosed prostate cancer (Briganti et al., 2010). Their results suggested that all patients with GS 8–10 and those with both the two other risk criteria should perform a BS. In our study, positive choline PET/CT findings were less common (12%) among men with one high-risk criterion only, so routine use of choline PET/CT in this subgroup of men with high-risk disease may not be cost-effective. However, the Briganti nomogram performed better than simple counting of high-risk criteria at discriminating between men with a low from men with a high risk of positive choline PET/CT findings. It is possible that some of the inconclusive scans in the present study represented metastatic disease, but as the proportion of inconclusive scans was similar regardless of the clinical risk of metastasis it is unlikely that a high proportion of these inconclusive findings represented metastases. Inflammatory response in lymph nodes may be responsible for some positive and inconclusive findings (Schwarz et al., 2016). The proportion of inconclusive scans is higher in the current than in previous studies. The reasons for this are unclear, but could possibly be related to the definitions of positive scans which vary from study to study.

Few of the studied patients with extra-iliac metastasis on PET/CT received treatment with curative intent, but there is an increasing interest in multimodal treatment of men with limited metastatic burden (Bayne et al., 2016). Surgical removal of lymph node metastases and stereotactic radiation to oligo-metastatic spread to lymph nodes and bone in men with biochemical recurrence after radical local treatment have been associated with favorable outcomes in institutional series (Osmonov et al., 2016; Suardi et al., 2015; Pasqualetti et al., 2016), and there is at least one ongoing randomized controlled trial of metastasis-directed treatment of oligo-metastasis following recurrence after previous local therapy (Decaestecker et al., 2014). The favorable outcome after treatment of oligo-metastatic recurrence suggests that combined local and metastasis-directed therapies might be of benefit for men with primary oligo-metastatic disease, but results from randomized trials are needed to prove a survival benefit.

The strengths of our study include its population-based design and that most of the men with high-risk disease had a choline PET/CT. The limitations are primarily related to the retrospective design and that the PET/CT scans were not reevaluated in a blinded fashion. Moreover, there seems to have been some selection of men with more



adverse prognostic factors for PET/CT scanning (Table 1). Finally, PET/CT could not be compared with the combination of CT and BS, which is the recommended metastasis staging in the EAU guidelines. The sensitivity of CT for detecting lymph node metastasis is, however, low and there is clearly a need for more sensitive imaging (Mottet et al., 2017). Other PET/CT tracers, such as  $^{11}\text{C}$ -acetate and various PSMA ligands, are available, but they have not been evaluated as extensively as choline, especially not regarding their clinical utility (Perera et al., 2016; Strandberg et al., 2016; von Eyben et al., 2016; Michaud & Touijer, 2017).

## Conclusions

In this population-based study,  $^{18}\text{F}$ -choline PET/CT for primary staging of high-risk prostate cancer detected suspected metastases in one fifth of the patients. The probability of positive findings on  $^{18}\text{F}$ -choline PET/CT was, however, low (1%) when the probability of lymph node metastasis according to the Briganti nomogram was less than 20%, suggesting that imaging (including the less sensitive modalities CT, MRI and BS) is not necessary in this subgroup of men with high-risk prostate cancer.

## Funding

This study was funded by a grant from the Department of Research and Development, Region Kronoberg (Henrik Kjölhede), and by the Swedish Cancer Foundation (Ola Bratt: grant number 2012/475).

## Authors' contributions

Conception and design: HK and OB. Acquisition of data: HK. Analysis and interpretation: HK and OB. Drafting and revising manuscript: HK, OB, KL, and HA. All authors read and approved the final manuscript.

## Ethics approval and consent to participate

The study protocol was approved by the Regional Ethics Committee in Lund (Dnr 2016/61). All still living patients gave written informed consent, while consent was assumed for deceased patients, according to Swedish law. No individual patient data is presented.

## Competing interests

The authors declare that they have no competing interest.

## Publisher's Note

Springer Nature remains neutral with regard to jurisdictional claims in published maps and institutional affiliations.

## Author details

<sup>1</sup>Department of Translational Medicine, Division of Urological Cancer, Lund University, Malmö, Sweden. <sup>2</sup>Department of Research and Development, Region Kronoberg, Växjö, Sweden. <sup>3</sup>Department of Medical Imaging and Physiology, Skåne University Hospital, Lund, Sweden. <sup>4</sup>CamPARI Clinic / Department of Urology, Cambridge University Hospitals, Cambridge, UK.

Received: 9 August 2017 Accepted: 30 October 2017

Published online: 28 November 2017

## References

- Bayne CE, Williams SB, Cooperberg MR, Gleave ME, Graefen M, Montorsi F et al (2016) Treatment of the primary tumor in metastatic prostate cancer: current concepts and future perspectives. *Eur Urol* 69(5):775–787
- Briganti A, Larcher A, Abdollah F, Capitanio U, Gallina A, Suardi N et al (2012) Updated nomogram predicting lymph node invasion in patients with prostate cancer undergoing extended pelvic lymph node dissection: the essential importance of percentage of positive cores. *Eur Urol* 61(3):480–487
- Briganti A, Passoni N, Ferrari M, Capitanio U, Suardi N, Gallina A et al (2010) When to perform bone scan in patients with newly diagnosed prostate cancer: external validation of the currently available guidelines and proposal of a novel risk stratification tool. *Eur Urol* 57(4):551–558
- Ceci F, Castellucci P, Graziani T, Schiavina R, Chondrogiannis S (2015) Bonfiglioli R, et al.  $^{11}\text{C}$ -choline PET/CT identifies osteoblastic and osteolytic lesions in patients with metastatic prostate cancer. *Clin Nucl Med* 40(5):e265–e270
- Decaestecker K, De Meerleer G, Ameye F, Fonteyne V, Lambert B, Joniau S et al (2014) Surveillance or metastasis-directed therapy for OligoMetastatic prostate cancer recurrence (STOMP): study protocol for a randomized phase II trial. *BMC Cancer* 14(1):671
- Evangelista L, Briganti A, Fanti S, Joniau S, Reske S, Schiavina R et al (2016) New clinical indications for  $(^{18}\text{F}/^{11}\text{C})$ -choline, new tracers for positron emission tomography and a promising hybrid device for prostate cancer staging: a systematic review of the literature. *Eur Urol* 70(1):161–175

- Evangelista L, Cimitan M, Zattoni F, Guttilla A, Zattoni F, Saladini G (2015) Comparison between conventional imaging (abdominal-pelvic computed tomography and bone scan) and [(18)F]choline positron emission tomography/computed tomography imaging for the initial staging of patients with intermediate- to high-risk prostate cancer: a Scand J Urol 49(5):345–353
- Evangelista L, Guttilla A, Zattoni F, Muzzio PC, Zattoni F (2013) Utility of choline positron emission tomography/computed tomography for lymph node involvement identification in intermediate- to high-risk prostate cancer: a systematic literature review and meta-analysis. *Eur Urol* 63(6):1040–1048
- Even-Sapir E, Metser U, Mishani E, Lievshitz G, Lerman H, Leibovitch I (2006) The detection of bone metastases in patients with high-risk prostate cancer: 99mTc-MDP planar bone scintigraphy, single- and multi-field-of-view SPECT, 18F-fluoride PET, and 18F-fluoride PET/CT. *J Nucl Med* 47(2):287–297
- von Eyben FE, Kairemo K (2014) Meta-analysis of (11)C-choline and (18)F-choline PET/CT for management of patients with prostate cancer. *Nucl Med Commun* 35(3):221–230
- Hansen J, Rink M, Bianchi M, Kluth L (2013) A, Tian Z, Ahyai S a, et al. external validation of the updated Briganti nomogram to predict lymph node invasion in prostate cancer patients undergoing extended lymph node dissection. *Prostate* 73(2):211–218
- Heck MM, Souvatzoglou M, Retz M, Nawroth R, Kübler H, Maurer T et al (2014) Prospective comparison of computed tomography, diffusion-weighted magnetic resonance imaging and [11C]choline positron emission tomography/computed tomography for preoperative lymph node staging in prostate cancer patients. *Eur J Nucl Med Mol Imaging* 41(4):694–701
- Heidenreich A, Bastian PJ, Bellmunt J, Bolla M, Joniau S, van der Kwast T et al (2014) EAU guidelines on prostate cancer. Part 1: screening, diagnosis, and local treatment with curative intent-update 2013. *Eur Urol* 65(1):124–137
- Kjölhede H, Ahlgren G, Almquist H, Liedberg F, Lyttkens K, Ohlsson T et al (2012) Combined 18F-fluorocholine and 18F-fluoride positron emission tomography/computed tomography imaging for staging of high-risk prostate cancer. *BJU Int* 110(10):1501–1506
- Langsteger W, Balogova S, Huchet V, Beheshti M, Paycha F, Egrot C et al (2011) Fluorocholine (18F) and sodium fluoride (18F) PET/CT in the detection of prostate cancer: prospective comparison of diagnostic performance determined by masked reading. *Q J Nucl Med Mol Imaging* 55(4):448–457
- Mapelli P, Picchio M (2015) Initial prostate cancer diagnosis and disease staging—the role of choline-PET-CT. *Nat Rev Urol* 12(9):510–518
- Michaud L, Toujier KA (2017) Molecular imaging for prostate cancer: performance analysis of (68)Ga-PSMA PET/CT versus choline PET/CT. *Actas Urol Esp* 41(5):292–299
- Mottet N, Bellmunt J, Bolla M, Briers E, Cumberbatch MG, De Santis M et al (2017) EAU-ESTRO-SIOG guidelines on prostate cancer. Part 1: screening, diagnosis, and local treatment with curative intent. *Eur Urol* 71(4):618–629
- Osmonov DK, Aksenov AV, Trick D, Naumann CM, Hamann MF, Faddan AA et al (2016) Cancer-specific and overall survival in patients with recurrent prostate cancer who underwent salvage extended pelvic lymph node dissection. *BMC Urol* 16(1):56
- Pasqualetti F, Panichi M, Sainato A, Matteucci F, Galli L, Cocuzza P et al (2016) [18F]Choline PET/CT and stereotactic body radiotherapy on treatment decision making of oligometastatic prostate cancer patients: preliminary results. *Radiat Oncol* 11(1):9
- Perera M, Papa N, Christidis D, Wetherell D, Hofman MS, Murphy DG et al (2016) Sensitivity, specificity, and predictors of positive 68Ga-prostate-specific membrane antigen positron emission tomography in advanced prostate cancer: a systematic review and meta-analysis. *Eur Urol* 70(6):926–937
- Pinaquy J-B, De Clermont-Galleran H, Pasticier G, Rigou G, Alberti N, Hindie E et al (2015) Comparative effectiveness of [(18) F]-fluorocholine PET-CT and pelvic MRI with diffusion-weighted imaging for staging in patients with high-risk prostate cancer. *Prostate* 75(3):323–331
- Porcaro AB, De Luyk N, Corsi P, Sebben M, Tafuri A, Processali T et al (2017) Clinical Factors Predicting Bilateral Lymph Node Invasion in High-Risk Prostate Cancer. *Urol Int*; doi:10.1159/000476039
- Risko R, Merdan S, Womble PR, Barnett C, Ye Z, Linsell SM et al (2014) Clinical predictors and recommendations for staging computed tomography scan among men with prostate cancer. *Urology* 84(6):1329–1334
- Schiavina R, Scattoni V, Castellucci P, Picchio M, Corti B, Briganti A et al (2008) 11C-choline positron emission tomography/computerized tomography for preoperative lymph-node staging in intermediate-risk and high-risk prostate cancer: comparison with clinical staging nomograms. *Eur Urol* 54(2):392–401
- Schwarz T, Seidl C, Schiemann M, Senekowitsch-Schmidtker R, Krause BJ (2016) Increased choline uptake in macrophages and prostate cancer cells does not allow for differentiation between benign and malignant prostate pathologies. *Nucl Med Biol* 43(6):355–359
- Strandberg S, Karlsson CT, Ogren M, Axelsson J, Riklund K (2016) 11C-acetate-PET/CT compared to 99mTc-HDP bone Scintigraphy in primary staging of high-risk prostate cancer. *Anticancer Res* 36(12):6475–6479
- Suardi N, Gandaglia G, Gallina A, Di Trapani E, Scattoni V, Vizziello D et al (2015) Long-term outcomes of salvage lymph node dissection for clinically recurrent prostate cancer: results of a single-institution series with a minimum follow-up of 5 years. *Eur Urol* 67(2):299–309
- Tomic K, Sandin F, Wigertz A, Robinson D, Lambe M, Stattin P (2015) Evaluation of data quality in the National Prostate Cancer Register of Sweden. *Eur J Cancer* 51(1):101–111
- von Eyben FE, Picchio M, von Eyben R, Rhee H, Bauman G (2016) (68)Ga-labeled prostate-specific membrane antigen Ligand positron emission tomography/computed tomography for prostate cancer: a systematic review and meta-analysis. *Eur Urol Focus*; doi:10.1016/j.euf.2016.11.002
- Wongergem M, van der Zant FM, van der Ploeg T, Knol RJJ (2013) A literature review of 18F-fluoride PET/CT and 18F-choline or 11C-choline PET/CT for detection of bone metastases in patients with prostate cancer. *Nucl Med Commun* 34(10):935–945