

CASE REPORT

Open Access



Incidental meningioma detected with [¹⁸F]-FDOPA PET/CT

Gilles N. Stormezand^{1*} , Andor W. J. M. Glaudemans¹, Riemer H. J. A. Slart^{1,2} and Rudi A. J. O. Dierckx¹

* Correspondence: g.n.stormezand01@umcg.nl

¹Department of Nuclear Medicine and Molecular Imaging, Medical Imaging Center, University Medical Center Groningen, University of Groningen, Hanzeplein 1, Groningen 9700 RB, The Netherlands

Full list of author information is available at the end of the article

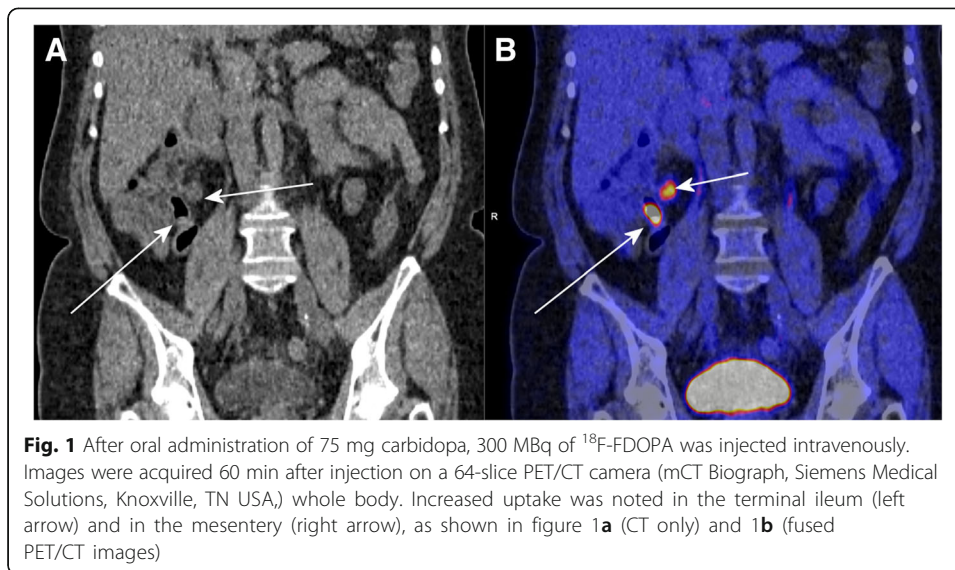
Abstract

A 59 year old patient was referred to our department to detect disease activity related to clinical symptoms of tiredness, weight loss and an elevated serum serotonin, suspicious of a neuro-endocrine tumour. A 18F-fluoro-l-dihydroxy-phenylalanine (FDOPA) PET/CT scan was performed, which showed focally increased uptake in the terminal ileum and in a mesenterial lymph node. Additionally, an area of intense uptake was observed intracranially. Histological analysis confirmed the presence of a WHO grade I meningioma. Few cases of FDOPA PET uptake in meningiomas have been published, underlining it is as a rare finding. Awareness of this potential finding is crucial to avoid misinterpretation as intracerebral metastasis.

Keywords: FDOPA, Neuro-endocrine tumours, Meningioma, Pitfalls, PET/CT, Brain tumours

A 59 year old patient was referred to our department to detect disease activity related to clinical symptoms of tiredness, weight loss and an elevated serum serotonin, suspicious of a neuro-endocrine tumour. A ¹⁸F-fluoro-l-dihydroxy-phenylalanine (FDOPA) PET/CT scan was performed, which showed focally increased uptake in the terminal ileum and in a mesenterial lymph node (Fig. 1). Additionally, an area of intense uptake was observed intracranially (Fig. 2a, left frontal region). The atypical location of the uptake suggested the presence of a meningioma (Fig. 2b). Based on this PET finding, MRI was performed (2C), which showed an extra-axial mass with extensive contrast enhancement on T1 weighted imaging and a 'dural tail', typical of meningioma. Additional findings on MRI were midline shift and edema. Histological analysis confirmed the presence of a WHO grade I meningioma.

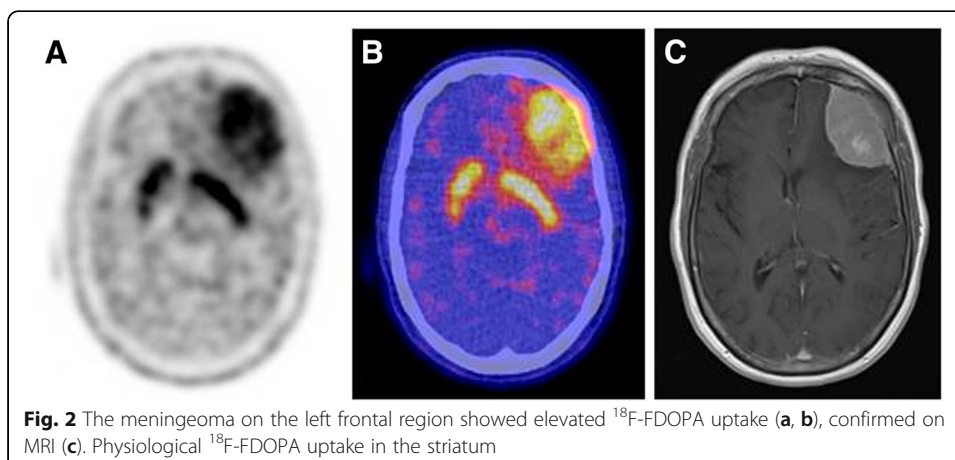
FDOPA PET has been used in the evaluation of brain tumours, among other PET techniques using amino acid tracers such as ¹¹C-methionine and -(2-[¹⁸F]fluoroethyl)-l-tyrosine (FET) (Becherer et al. 2003; Fueger et al. 2010; Schiepers et al. 2007). The increased uptake of FDOPA is related to the L amino acid transporter (LAT). The LAT facilitates amino acid transport in



tumour cells, which in turn use it for protein synthesis. In meningiomas, high LAT1 expression has been described (Zitron et al. 2013). Consequently, increased uptake of FDOPA may be observed in these tumours. In addition, increased uptake of other amino acid PET tracers in meningiomas has been described, including a series of 10 meningiomas which showed increased uptake of $^{-[11\text{C}]}$ methyl-L-tryptophan (AMT) (Zitron et al. 2013). as well as of somatostatin radiolabelled analogs (Soto-Montenegro et al. 2014).

Conclusions

Few cases of FDOPA PET uptake in meningiomas have been published (Calabria et al. 2016), underlining it is as a rare finding. Awareness of this potential finding is crucial to avoid misinterpretation as intracerebral metastasis.



Abbreviations

AMT: Methyl-L-tryptophan; FDOPA: Fluoro-L-dihydroxy-phenylalanine; FET: Fluoroethyl)-L-tyrosine; LAT: L amino acid transporter

Acknowledgments

The publication of this article was supported by funds of the European Association of Nuclear Medicine (EANM).

Authors' contributions

GNS: writing of the manuscript, lay-out, images. AWJMG, RHJAS, RAJOD: review of the article, providing comments. All authors read and approved the final manuscript.

Competing interests

The authors declare that they have no competing interests.

Publisher's Note

Springer Nature remains neutral with regard to jurisdictional claims in published maps and institutional affiliations.

Author details

¹Department of Nuclear Medicine and Molecular Imaging, Medical Imaging Center, University Medical Center Groningen, University of Groningen, Hanzeplein 1, Groningen 9700 RB, The Netherlands. ²Department of Biomedical Photonic Imaging, University of Twente, Enschede, The Netherlands.

Received: 6 June 2018 Accepted: 23 August 2018

Published online: 20 November 2018

References

- Becherer A, Karanikas G, Szabo M, Zettinig G, Asenbaum S, Marosi C et al (2003) Brain tumour imaging with PET: a comparison between [18F]fluorodopa and [11C]methionine. *Eur J Nucl Med Mol Imaging* 30(11):1561–1567
- Calabria FF, Chiaravalloti A, Calabria EN, Grillea G, Schillaci O (2016) 18F-DOPA PET/CT and MRI findings in a patient with multiple Meningiomas. *Clin Nucl Med* 41(8):636–637
- Fueger BJ, Czernin J, Cloughesy T, Silverman DH, Geist CL, Walter MA et al (2010) Correlation of 6-18F-fluoro-L-dopa PET uptake with proliferation and tumor grade in newly diagnosed and recurrent gliomas. *J Nucl Med* 51(10):1532–1538
- Schiepers C, Chen W, Cloughesy T, Dahlbom M, Huang SC (2007) 18F-FDOPA kinetics in brain tumors. *J Nucl Med* 48(10):1651–1661
- Soto-Montenegro ML, Pena-Zalbidea S, Mateos-Perez JM, Oteo M, Romero E, Morcillo MA et al (2014) Meningiomas: a comparative study of 68Ga-DOTATOC, 68Ga-DOTANOC and 68Ga-DOTATATE for molecular imaging in mice. *PLoS One* 9(11):e111624
- Zitron IM, Kamson DO, Kiousis S, Juhasz C, Mittal S (2013) In vivo metabolism of tryptophan in meningiomas is mediated by indoleamine 2,3-dioxygenase 1. *Cancer Biol Ther* 14(4):333–339

Submit your manuscript to a SpringerOpen[®] journal and benefit from:

- Convenient online submission
- Rigorous peer review
- Open access: articles freely available online
- High visibility within the field
- Retaining the copyright to your article

Submit your next manuscript at ► springeropen.com